Lasers in Medical Science
https://doi.org/10.1007/s10103-018-2507-8

ORIGINAL ARTICLE

A 1470-nm laser combined with foam sclerotherapy in day surgery: a better choice for lower limb varicose veins

Xing Zhang[1] · Xin Wang[1] · Cheng Gao[2] · Jinbao Qin[1] · Haiguang Zhao[1,3] · Weimin Li[1] · Xinwu Lu[1]

Received: 9 January 2018 / Accepted: 10 April 2018

Abstract

Day surgery is being more and more adopted by clinicians. Higher wavelength lasers give patients better experience than lower wavelength lasers, which makes it more suitable for day surgery. This study compares the short- and mid-term efficacy, postoperative morbidity, and patient satisfaction of "1470-nm endovenous laser ablation (EVLA) combining foam sclerotherapy in day surgery" with "810-nm EVLA with high ligation combining foam sclerotherapy in hospital surgery" on great saphenous vein (GSV) insufficiency postoperatively. A single-institution historical cohort study of 194 patients was performed in Shanghai Ninth People's Hospital, China. Ninety-seven patients received 1470-nm EVLA combining foam sclerotherapy in day surgery ("1470-nm group"), and 97 patients received 810-nm EVLA with high ligation combining foam sclerotherapy in hospital surgery recommended by guidelines ("810-nm group"). No significant difference was found between the 1470-nm group and the 810-nm group in terms of GSV occlusion rate (both 100%), complication rate, and recurrence rate (8.2 vs. 11.3%) during the period of 1–12 months after surgery. Serious complications in the 1470-nm group and 810-nm group were 0 and 1.0%. Minor complications in the 1470-nm group and 810-nm group were ecchymosis at 20.6 and 18.6%, edema at 69.1 and 63.9%, and paresthesia around ankle at 0 and 3.1%, respectively. Advantage of the 1470-nm group over the 810-nm group was statistically significant considering the patient perioperative comfort and economic cost. Treatment of 1470-nm EVLA combining foam sclerotherapy in day surgery has similar efficacy as the 810-nm EVLA with high ligation combining foam sclerotherapy in hospital surgery in GSV insufficiency and is more comfortable with less incision, hospitalization procedure, and medical costs. It may be a new option for patients who are afraid or unable to be hospitalized.

Keywords Endovenous laser treatment · Foam sclerotherapy · Varicose veins · Day surgery

Xing Zhang, Xin Wang and Cheng Gao contributed equally to this work.

✉ Haiguang Zhao
sevilla2011@163.com

✉ Weimin Li
liweimin71@hotmail.com

✉ Xinwu Lu
luxinwu@shsmu.edu.cn

[1] Department of Vascular Surgery, Shanghai Ninth People's Hospital, Shanghai JiaoTong University School of Medicine, Shanghai 200011, China

[2] The Affiliated Central Hospital of Qingdao University, Qingdao 266071, Shandong, China

[3] Laser Cosmetic Center, Shanghai Ninth People's Hospital, Shanghai JiaoTong University School of Medicine, Shanghai 200011, China

Introduction

Lower limb varicose vein is the most common and early clinical symptom of chronic venous insufficiency, as well as one of the most common diseases in vascular surgery. This disease has been reported to affect 60% of the adult population, particularly populations in the developed world [1]. In the advanced stages, varicose veins may lead to ulcers and thrombosis, posing a serious threat to human health and life quality [1]. Clinically, varicose veins are accurately called as chronic venous insufficiency (CVI). Varicose veins, edema, skin pigmentation, and ulcers are the four major symptoms of CVI and also the four parameters to be used in the clinical severity, etiology, anatomy and pathophysiology (CEAP) classification system [2]. With the rapid development of intervention and sclerotherapy technology, various mini-invasive treatment methods are

Published online: 23 April 2018

available now, while the traditional high ligation treatment co-exists [2, 3]. Mini-invasive endovenous procedures (MIEPs) are accepted by a large number of clinicians. MIEPs mainly include endovenous laser ablation (EVLA), ultrasound-guided foam sclerotherapy, and radio frequency ablation (RFA), among which, the safe and effective EVLA technology is widely used to treat lower limb varicose veins in Europe and North America, and are developing vigorously in Asia [4, 5]. In recent years, higher wavelength lasers like 1320-, 1470-, and 1500-nm lasers have been introduced as more selectively absorbed by chromophores (hemoglobin, water, proteins) than lower wavelength lasers like 810-, 940-, and 980-nm lasers [1]. Higher wavelength lasers have been reported to have equal occlusion rates (97–100%) and less postoperative pain than lower wavelength lasers [6, 7]. But there still lacks enough evidence to prove the advantages of higher wavelength lasers over lower wavelength lasers. Day surgery is becoming more and more popular with clinicians and hospitals, and EVLA is suitable to be performed in day surgery settings [8]. Thus, the less painful 1470-nm laser may be a preferred choice to be performed in day surgery, which gives patients better experience and quicker recovery. In our study, foam sclerotherapy was adopted for the great saphenous vein (GSV) under the knee and other superficial varicose veins in both groups as recommended by the guideline. Our real-word experience may also give an insight into a new option for CVI patients, who are afraid or unable to be hospitalized.

The aim of this single-institution historical cohort study was to compare the short- and mid-term efficacy, early post-operative morbidity, patient satisfaction, and effects on venous clinical severity score (VCSS) of two different overall treatment programs: the "1470-nm EVLA combining foam sclerotherapy in day surgery" and "810-nm EVLA with high ligation combining foam sclerotherapy in hospital surgery" in the treatment of lower limb varicose veins (C3–C5).

Materials and methods

Study design

The study was approved by the Committee for the Protection of Human Subjects at the Shanghai Jiao Tong University, School of Medicine (Shanghai, China). Informed consent was obtained from each patient involved in this study. This single-center historical cohort study included all sequential patients from June 2015 to June 2017 who received an overall treatment program of 1470-nm EVLA combining foam sclerotherapy in day surgery ("1470-nm group"). Comparisons were made with matched sequential patients who received an overall treatment program of 810-nm EVLA with high ligation combining foam sclerotherapy recommended by guidelines in hospital surgery ("810-nm group"). Both groups were treated in the division of vascular surgery, Shanghai Ninth People's Hospital in China.

Inclusion criteria and exclusion criteria

The inclusion criteria were as follows: (1) age 18–85 years; (2) chose unilateral limbs with the clinical symptom of varicose veins (C3–C5). Flows in deep veins of lower limbs were examined by color Doppler ultrasound and venography examinations to ensure the lower extremity veins open (Fig. 1a). (3) The average diameters of the veins at the saphenofemoral junction (SFJ) and at the knee level were larger than 6 mm in the supine position. (4) There is a reflux/retrograde flow with a duration of 0.5 s or greater after a Valsalva maneuver, in the proximal part of the vein, or manual compression and decompression of the calf to assess the distal part of the vein.

The exclusion criteria were as follows: (1) previous surgery or sclerotherapy treatment for lower limb varicose veins; (2) hypersensitive reaction to sclerotherapy; (3) serious systematic diseases, New York Heart Association C or D [9], heart disease induced by right-to-left shunt, and chronic obstructive pulmonary disease moderate or above; (4) serious lower limb ischemia disease (lower extremity arteriosclerosis obliterans, thromboangiitis obliterans, acute arterial embolism, Renault syndrome) or abnormal sensation history; and (5) coagulation disorder.

Treatment procedures

The GSV of all patients and superficial varicose veins were marked in the standing position. The diameters of the veins at SFJ and knees were measured in the supine position. The average diameters of all saphenous main vein were ≥ 6 mm (Fig. 1b).

Preparation of sclerosing foam

Two 5-mL syringes were filled with 1 mL of polidocanol (Chemische Fabrik Kreussler & Co. GmbH, approval number H20140116) and 4 mL of air using the Tessari [10] method. The reagent should be used immediately after preparation. Through a tee joint, 5 mL of sclerosing foam was prepared in the ratio of 1:4, which appeared to be Ivory micro-foam.

Surgical procedures and postoperative management

The 1470-nm group The patients of the 1470-nm group were treated in the day surgery setting. GSV at the knee level was punctured after local anesthesia with 2% (1%) lidocaine under ultrasound (US) guidance. The needle core was drawn back, and a guide wire was inserted. Then, a 5F introducer sheath was inserted through the guide wire, and finally through the introducer sheath, a radial fiber for 1470-nm laser (LASEmaR1500 and radial fiber, Eufoton S.R.L., Italy) was

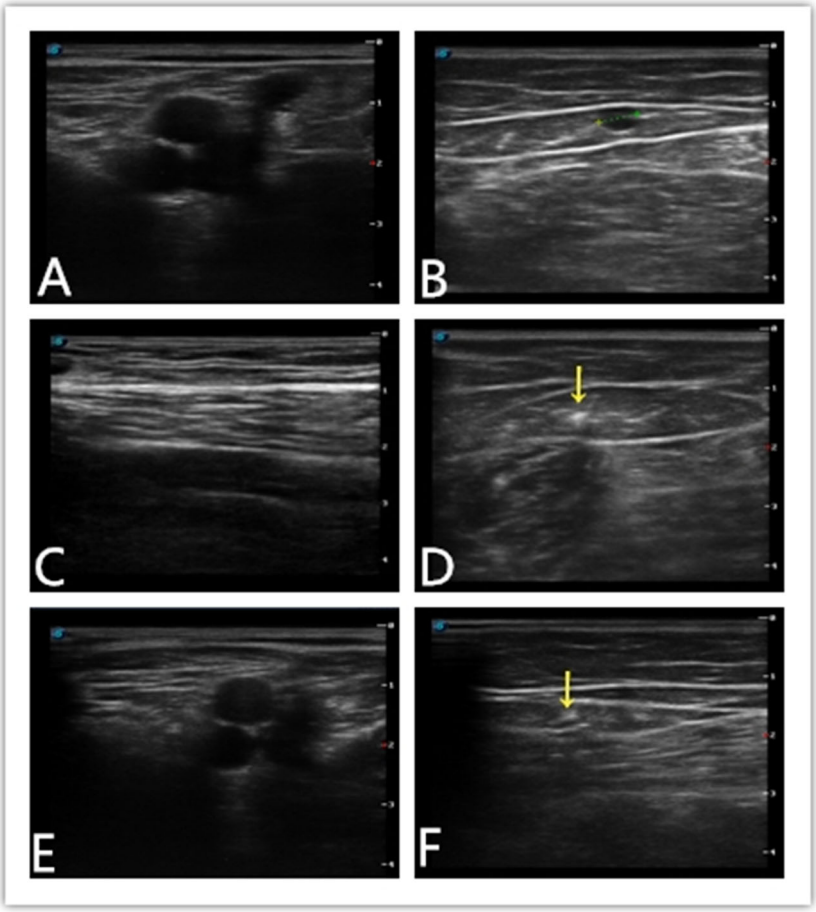

Fig. 1 **a** SFJ before surgery: open deep vein. **b** GSV before surgery (diameter 6.05 mm). **c** Insertion of the fiber into GSV. **d** GSV after surgery (occluded to a point). **e** After surgery: GSV occluded and open deep vein. **f** Follow-up: 12 months after surgery, GSV occluded

inserted, with a nylon jacket on the fiber body and a glass protective cap on the radial fiber tip. The radial fiber was placed around 2 cm under SFJ. Under the US (Kaili, Shenzhen, China) guidance, a 20-gauge puncture needle was advanced from the proximal to the distal end along the GSV (Fig. 1c). Tumescent local anesthesia (0.1% saline 500 mL, 2% lidocaine 25 mL, adrenaline 0.5 mL, and 8.4% sodium bicarbonate 475 mL) was delivered [11]. The limb position was raised to 30°. The 1470-nm laser device was set under continuous mode using 8 W of power. The radial fiber was drawn back at the speed of 10 mm/s while compressing the limb along the GSV. 0.5–3 mL of sclerosing foam (1%, 1:4) at each site was injected to occlude the remaining superficial varicose veins. The total administered volume did not exceed 10 mL. The US equipment was used to confirm that no remaining GSVs and collateral veins were missed (Fig. 1d, e), followed by proper bandaging.

After eccentric elastic bandage and elastic stocking were applied, the patients were instructed to pace in the room for 30 min. They were discharged immediately if no obvious anomaly was observed in 2 h. The eccentric elastic bandage was removed in 3 days. The elastic stocking should be worn for at least 3 months. Oral medicines such as Aescuven forte and diosmin tablets were administered for 3 months.

The 810-nm group The patients in the 810-nm group were treated as previously described by Ying Huang et al. [12]. Briefly after general anesthesia without tumescent anesthesia, a 1- to 2-cm incision was cut at the round dimple on the groin for high ligation of GSV and a laser fiber for the 810-nm laser (Diomed, Ltd., Cambridgeshire, UK) was inserted. The 810-nm laser device was set under continuous mode using 14 W of power. The bare-tip fiber was drawn back at the speed of 10 mm/s while compressing the limb along the GSV. The remaining superficial varicose veins were treated in the same way as in the 1470-nm group. The US equipment (Kaili, Shenzhen, China) was used to confirm that no remaining GSVs or collateral veins were missed.

The patients were instructed to resume walking immediately after recovery from anesthesia. An eccentric elastic bandaging was done for 3 days, followed by elastic stocking being worn for at least 3 months. They were discharged after 2 days of intravenous drip treatment in the hospital. Oral medicines like Aescuven forte and diosmin tablets were administered for at least 3 months.

Parameters

Visual analog scale (VAS) ranging from 1 to 5 were used to measure the postoperative pain [8]: 1, no pain; 2, minor pain; 3, medium pain; 4, severe pain; and 5, extreme pain. Analgesic intake was recorded. The patients were encouraged to resume walk and daily life as early as possible. The time needed for patients to return to daily life was recorded. All the recording work was done by at least two experienced phlebologists blinded to the interventions. The US examination was performed for GSV and other superficial varicose veins immediately after the operation by a professional technician not involved in the performance of the initial treatment.

Follow-up

Post-interventional checkups took place at 1, 2, 6, and 12 months after the surgery. During the follow-up, the patients were asked about their recovery status and complications. Also, the recurrence of varicose veins was checked visually or by ultrasound. The venous clinical severity score (VCSS) scores of the first-month visit were recorded. The complications and recurrences were assessed mainly during the following visits. The recurrence was the end point of follow-up visits. US examinations were performed by professional technicians unaware of the treatment type (Fig. 1f). All the recording work was done by at least two experienced phlebologists blinded to the interventions.

(1) Treatment effect [12]: Cured: no visible varicose veins. Symptoms disappeared or improved. No blood flow within the ablated saphenous veins was found under color ultrasonic examination. Effective: small visible varicose veins. Symptoms disappeared or improved. A little blood flow was found under color ultrasonic examination. Treatment failure: no improvement in varicose veins or the symptoms. Obvious blood flow was found under color ultrasonic examination.
(2) Complications and adverse events: skin burns, local paresthesia, local inflammatory mass, allergic reaction, deep-vein thrombosis (DVT), and local recurrences.

Statistical analysis

Data were described using mean ± standard deviation (SD) or as median and range. The *t* test was used for comparing measurement data, and the χ^2 test was used for comparing count data between the two groups. Data analyses were performed using SPSS version 19.0 software (SPSS, IL, USA). A *P* value less than 0.05 was regarded as statistically significant.

Results

The 1470-nm group consisted of 97 eligible patients: 50 males and 47 females with the average age of 59.27 ± 9.49 years. The 810-nm group included 97 eligible patients from the same period: 52 males and 45 females with the average age of 57.31 ± 7.24 years. All the patients of the 1470-nm group and 810-nm group met the aforementioned inclusion criteria and patients in the 1470-nm group were all strongly against hospital surgery option.

No significant differences in gender, age, and preoperative data were observed between the two groups, such as CEAP scores, VCSS scores, GSV diameter at SFJ and knee level, and reflux duration at the SFJ valve after a Valsalva maneuver ($P > 0.05$). Demographic details and results are shown in Table 1. Patients in the two groups are very similar.

The group with 1470-nm EVLA combining foam sclerotherapy was favored in terms of postoperative pain and pain duration; the difference between the groups was significant ($P < 0.05$). All patients from the 1470-nm EVLA combining foam sclerotherapy group could tolerate the treatment well, and none of them took analgesics. VCSS score changes in both groups between pre- and post-surgery were significant ($P < 0.05$). This study reported that the clinical efficacy of the 1470-nm group was slightly better than that of the 810-nm group.

The time needed to resume walking and a normal daily life was significantly different between the two groups ($P < 0.05$). The patients from the 1470-nm group needed shorter time. The economic cost of the 1470-nm group was much lower than that of the 810-nm group ($P < 0.05$) (Table 2).

It was confirmed by color US that both groups in our study achieved 100% technical success. No significant difference was found between the 1470-nm group and the 810-nm group in terms of GSV occlusion rate (both 100%), complication rate, and recurrence rate (8.2 vs. 11.3%) during the period of 1–12 months after surgery (Table 3). Serious complications in the 1470-nm group and 810-nm group were 0 and 1.0%. Minor complications in the 1470-nm group and 810-nm group were ecchymosis at 20.6 and 18.6%, edema at 69.1 and 63.9%, and paresthesia around ankle at 0 and 3.1%, respectively. One patient had angina in the 810-nm group. This patient was later cured and discharged. DVT was diagnosed in one patient from the 810-nm group. With the active anticoagulation therapy, this patient was treated successfully and discharged. No paresthesia around the ankle, DVT, or other serious complications was found in the 1470-nm group.

Discussion

Nowadays, day surgery is attracting increasing attention from clinicians [13]. It also becomes a trend in hospitals in China,

Table 1 Comparison of the baseline data of the 810-nm group and 1470-nm group

	The 810-nm group ($n = 97$)	The 1470-nm group ($n = 97$)	P values
Gender (M/F)	52/45	50/47	0.886
Mean age (year)	57.31 ± 7.24	59.27 ± 9.49	0.108
Preoperative VCSS	9.73 ± 3.14	10.11 ± 2.83	0.377
Mean GSV diameter at the SFJ level (mm)	7.33 ± 1.47	7.51 ± 1.10	0.336
Mean GSV diameter at the knee level (mm)	5.78 ± 0.37	5.83 ± 0.29	0.296
Reflux duration at the SFJ level (ms)	763.25 ± 70.32	754.23 ± 75.10	0.389
CEAP (n) %			
C3	64 (66)	62 (64)	
C4	28 (29)	27 (28)	
C5	5 (5)	8 (8)	

The 810-nm group—the 810-nm EVLA with high ligation combining foam sclerotherapy in hospital surgery. The 1470-nm group—the 1470-nm EVLA combining foam sclerotherapy in day surgery. Data were described using mean ± standard deviation (SD). A P value less than 0.05 was regarded as statistically significant

CEAP clinical severity, etiology, anatomy and pathophysiology; *VCSS* venous clinical severity score; *GSV* great saphenous vein; *SFJ* saphenofemoral junction

for it may be an effective solution for the increasing patient population and China's resident medical insurance cost. EVLA is suitable to perform as a day-case surgery and in many centers, it is performed under standard local tumescent anesthesia [14], which is also recommended by the 2011 Society for Vascular Surgery (SVS) guideline [8]. Day surgery has the advantage of lower medical cost, simplified hospitalization procedure, and so on [15]. As a number of CVI patients are afraid of being hospitalized or strongly against general anesthesia, day surgery is a feasible solution for many hospitals and patients themselves.

The 1470-nm laser and 810-nm laser systems were both recommended by the 2011 SVS guideline for EVLA, and higher wavelength like 1470-nm laser was reported to have successful endovenous ablation by Pannier et al. [6]. Doganci S et al. reported a RCT comparison of 1470-nm laser and 980-nm laser, with the conclusion of treatment of the GSV by endovenous laser ablation using a 1470-nm laser and a radial fiber, resulted in less postoperative pain and better VCSS scores in the first month than treatment with a 980-nm laser and a bare-tip fiber [16]. Aktas A. R. et al. compared the 1470-nm laser and 980-nm laser in EVLA and concluded that EVLA with the 1470-nm laser has less energy deposition for occlusion and better treatment response [17]. But there is still a need for stronger evidence.

As the 1470-nm laser was reported to have better patient experience, in our study, we chose EVLA treatment with the 1470-nm laser and radial fiber to treat patients in the day surgery setting under tumescent anesthesia according to the 2011SVS guideline, in contrast with the regular treatment procedure 810-nm EVLA with high ligation combining foam sclerotherapy in hospital surgery as recommended by the

Table 2 Comparisons of postoperative pain, activities, and economic cost

	The 810-nm group ($n = 97$)	The 1470-nm group ($n = 97$)	P values
Pain duration (day)	4.27 ± 1.38	0.93 ± 0.38	< 0.001
Analgesia uses (cases)	3	0	0.246
Pain score	2.37 ± 0.79	1.65 ± 0.43	< 0.001
VCSS difference between pre- and post-surgery	6.03 ± 1.57	6.84 ± 2.12	< 0.01
Resume walk (day)	1.81 ± 1.42	0.01 ± 0.01	< 0.001
Resume daily life (day)	6.67 ± 3.16	1.45 ± 0.47	< 0.001
Economic cost (RMB)	13,475.14 ± 787.33	5045.35 ± 753.64	< 0.001

The 810-nm group—the 810-nm EVLA with high ligation combining foam sclerotherapy in hospital surgery. The 1470-nm group—the 1470-nm EVLA combining foam sclerotherapy in day surgery. Data were described using mean ± standard deviation (SD). A P value less than 0.05 was regarded as statistically significant

VCSS venous clinical severity score

Table 3 Postoperative complications

	The 810-nm group ($n = 97$)	The 1470-nm group ($n = 97$)	*P* values
Induration	97	97	–
Ecchymosis	18	20	0.857
Edema	62	67	0.543
Paresthesia around ankle	3	0	0.246
Chest tightness/dry cough	0	0	–
Visual obstacle	0	0	–
DVT in lower limbs	1	0	1
Pulmonary embolism	0	0	–
Other serious complications	1	0	1
Recurrence	11	8	0.630

The 810-nm group—the 810-nm EVLA with high ligation combining foam sclerotherapy in hospital surgery. The 1470-nm group—the 1470-nm EVLA combining foam sclerotherapy in day surgery. A *P* value less than 0.05 was regarded as statistically significant

DVT deep vein thrombosis

guideline, and the therapeutic effect of the regular 810-nm treatment procedure was first reported internationally by Huang et al. in our hospital [12].

The GSV was punctured at the knee level with reference to the RFA technology because of the strong ablation energy from the aforementioned system. Hence, saphenous nerve injury could be avoided. Multiple punctures are needed in EVLA while the superficial GSV under the knee connects closely with saphenous nerves. Uncontrolled laser energy transmitted by traditional bare fibers may burn the skin and, in some rare cases, even break the bare fibers leaving the remaining fragments in the patient body [18]. That is why we used foam sclerotherapy for the GSV under the knee and other superficial varicose veins of all patients in the 810-nm group and 1470-nm group [19].

The aim of this study was to obtain similar efficacy with 810-nm EVLA with high ligation combining foam sclerotherapy in treating the upper GSV using 1470-nm EVLA combining foam sclerotherapy and at the same time avoid the injury to saphenous nerves under the knee. More importantly, the GSV was not ligated. A sufficient tumescent solution was delivered beside GSV from the SFJ to the knee level while compressing GSV to avoid air embolism and shedding of thrombus. Hence, the fiber could also contact the vein wall more closely. This study also confirmed that no shedding of thrombus occurred in the 1470-nm EVLA combining foam sclerotherapy group. The 1470-nm group was superior to the 810-nm group in avoiding saphenous nerve injury under the knee with fewer complications. Serious complications were not reported in the present study.

In this study, we provided a real-world experience of two different treatment programs; the result is consistent with previous researches on the advantages of the 1470-nm laser over lower wavelengths in EVLA [6, 7, 16, 17]. However, previous studies focused more on the comparison of two different wavelengths; we first compared the two overall treatment programs widely used clinically, which may serve as a real-world evidence for the promotion of the 1470-nm EVLA combining foam sclerotherapy in day surgery.

This study confirmed that an overall treatment program of 1470-nm EVLA combining foam sclerotherapy in day surgery has similar efficacy as 810-nm EVLA with high ligation combining foam sclerotherapy in hospital surgery in GSV insufficiency and is more comfortable with less incision, hospitalization procedure, and medical costs. Based on these advantages, clinicians are expected to gain a better patient compliance and post-surgery satisfaction, which in turn facilitates the progress of clinical diagnosis and treatment.

However, there still exist limitations in this study: a single-centered retrospective study with limited samples, no blinded methods, the observation indicators were mainly scales and scores, and lack of objective indicators; and the follow-up period was not long enough, and more random controlled trials on the difference between these two overall treatment programs are needed for stronger evidence. Thus, we are planning on a multi-centered random controlled trial study with more samples in China to provide a strong evidence.

Conclusions

The 1470-nm EVLA combining foam sclerotherapy and high ligation combining EVLA therapy have similar efficacy in treating lower limb varicose veins (C3–C5). However, the former is superior in terms of incision size, patient comfort, time needed to resume work and daily life, and complication occurrence rate. Further studies are needed because of the limited sample size in this study. It is believed that the 1470-nm EVLA combining foam sclerotherapy in day surgery is a better option for those eligible patients who reject hospital

surgery or cannot tolerate surgery with general anesthesia. For them, this therapy can reduce the medical cost, operation risk, and postoperative complications.

Acknowledgements We sincerely thank Professor Lu Xinwu and Doctor Li Weimin for the enlightening discussions.

Funding information This work is supported by the National Natural Science Foundation of China (81601621, 81370423, 81570432).

Compliance with ethical standards

Conflict of interest The authors declare that they have no conflict of interest.

Ethical approval The study was approved by the Committee for the Protection of Human Subjects at the Shanghai Jiao Tong University, School of Medicine (Shanghai, China).

References

1. Wittens C, Davies AH, Baekgaard N, Broholm R, Cavezzi A, Chastanet S, de Wolf M, Eggen C, Giannoukas A, Gohel M, Kakkos S, Lawson J, Noppeney T, Onida S, Pittaluga P, Thomis S, Toonder I, Vuylsteke M, Kolh P, de Borst GJ, Chakfe N, Debus S, Hinchliffe R, Koncar I, Lindholt J, de Ceniga MV, Vermassen F, Verzini F, De Maeseneer MG, Blomgren L, Hartung O, Kalodiki E, Korten E, Lugli M, Naylor R, Nicolini P, Rosales A (2015) Editor's choice—management of chronic venous disease: clinical practice guidelines of the European Society for Vascular Surgery (ESVS). Eur J Vasc Endovasc Surg 49(6):678–737. https://doi.org/10.1016/j.ejvs.2015.02.007
2. Gloviczki P, Gloviczki ML (2012) Guidelines for the management of varicose veins. Phlebology 27(Suppl 1):2–9
3. Edwards AG, Baynham S, Lees T, Mitchell DC (2009) Management of varicose veins: a survey of current practice by members of the Vascular Society of Great Britain and Ireland. Ann R Coll Surg Engl 91(1):77–80. https://doi.org/10.1308/003588409X358953
4. Yamaki T, Hamahata A, Soejima K, Kono T, Nozaki M, Sakurai H (2012) Prospective randomised comparative study of visual foam sclerotherapy alone or in combination with ultrasound-guided foam sclerotherapy for treatment of superficial venous insufficiency: preliminary report. Eur J Vasc Endovasc Surg 43(3):343–347. https://doi.org/10.1016/j.ejvs.2011.07.029
5. Kanwar A, Hansrani M, Lees T, Stansby G (2010) Trends in varicose vein therapy in England: radical changes in the last decade. Ann R Coll Surg Engl 92(4):341–346. https://doi.org/10.1308/003588410X12518836440649
6. Pannier F, Rabe E, Rits J, Kadiss A, Maurins U (2011) Endovenous laser ablation of great saphenous veins using a 1470 nm diode laser and the radial fibre—follow-up after six months. Phlebology 26(1):35–39. https://doi.org/10.1258/phleb.2010.009096
7. Vuylsteke M, De Bo T, Dompe G, Di Crisci D, Abbad C, Mordon S (2011) Endovenous laser treatment: is there a clinical difference between using a 1500 nm and a 980 nm diode laser? A multicenter randomised clinical trial. Int Angiol 30:327–334
8. Arun O, Oc B, Duman A, Yildirim S, Simsek M, Farsak B, Oc M (2014) Endovenous laser ablation under general anesthesia for day surgery: feasibility and outcomes of the 300 patients. Ann Thorac Cardiovasc Surg 20(1):55–60. https://doi.org/10.5761/atcs.oa.13-00222
9. Yancy CW, Jessup M, Bozkurt B, Butler J, Casey DE Jr, Colvin MM, Drazner MH, Filippatos G, Fonarow GC, Givertz MM, Hollenberg SM, Lindenfeld J, Masoudi FA, McBride PE, Peterson PN, Stevenson LW, Westlake C (2016) 2016 ACC/AHA/HFSA focused update on new pharmacological therapy for heart failure: an update of the 2013 ACCF/AHA Guideline for the Management of Heart Failure: a report of the American College of Cardiology/American Heart Association Task Force on Clinical Practice Guidelines and the Heart Failure Society of America. J Am Coll Cardiol 68(13):1476–1488
10. Tessari L, Cavezzi A, Frullini A (2001) Preliminary experience with a new sclerosing foam in the treatment of varicose veins. Dermatol Surg 27(1):58–60. https://doi.org/10.1046/j.1524-4725.2001.00192.x
11. Rasmussen LH, Bjoern L, Lawaetz M, Blemings A, Lawaetz B, Eklof B (2007) Randomized trial comparing endovenous laser ablation of the great saphenous vein with high ligation and stripping in patients with varicose veins: short-term results. J Vasc Surg 46(2):308–315. https://doi.org/10.1016/j.jvs.2007.03.053
12. Huang Y, Jiang M, Li W, Lu X, Huang X, Lu M (2005) Endovenous laser treatment combined with a surgical strategy for treatment of venous insufficiency in lower extremity: a report of 208 cases. J Vasc Surg 42(3):494–501; discussion 501. https://doi.org/10.1016/j.jvs.2005.02.051
13. Roberts L (2006) Day surgery—national and international: from the past to the future. Ambul Surg 12(3):143–145. https://doi.org/10.1016/j.ambsur.2005.02.002
14. Chen JQ, Xie H, Deng HY, Yuan K, Zhang JW, Zhang H, Zhang L (2013) Endovenous laser ablation of great saphenous vein with ultrasound-guided perivenous tumescence: early and midterm results. Chin Med J 126(3):421–425. https://doi.org/10.3760/cma.j.issn.0366-6999.20122290
15. Carroll C, Hummel S, Leaviss J, Ren S, Stevens JW, Everson-Hock E, Cantrell A, Stevenson M, Michaels J (2013) Clinical effectiveness and cost-effectiveness of minimally invasive techniques to manage varicose veins: a systematic review and economic evaluation. Health Technol Assess 17(48):i-xvi, 1–141
16. Doganci S, Demirkilic U (2010) Comparison of 980 nm laser and bare-tip fibre with 1470 nm laser and radial fibre in the treatment of great saphenous vein varicosities: a prospective randomised clinical trial. Eur J Vasc Endovasc Surg 40(2):254–259. https://doi.org/10.1016/j.ejvs.2010.04.006
17. Aktas AR, Celik O, Ozkan U, Cetin M, Koroglu M, Yilmaz S, Daphan BU, Oguzkurt L (2015) Comparing 1470- and 980-nm diode lasers for endovenous ablation treatments. Laser Med Sci 30(5):1583–1587. https://doi.org/10.1007/s10103-015-1768-8
18. Bozoglan O, Mese B, Inci MF, Eroglu E (2013) A rare complication of endovenous laser ablation: intravascular laser catheter breakage. BMJ Case Rep 2013. https://doi.org/10.1136/bcr-2013-009012
19. Breu FX, Guggenbichler S (2004) European consensus meeting on foam sclerotherapy, April, 4–6, 2003, Tegernsee, Germany. Dermatol Surg 30(5):709–717; discussion 717. https://doi.org/10.1111/j.1524-4725.2004.30209.x